



Reception Area
Patient Information

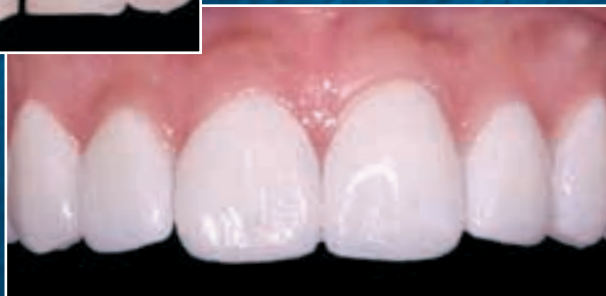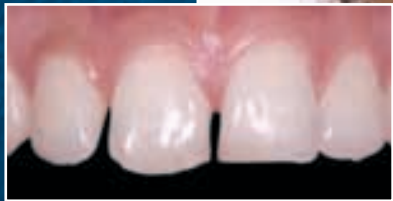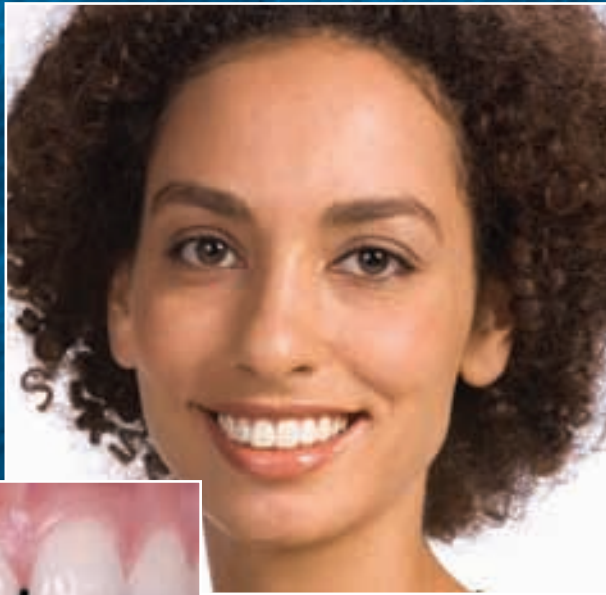The
Beauty
of

Ceramic
Veneers



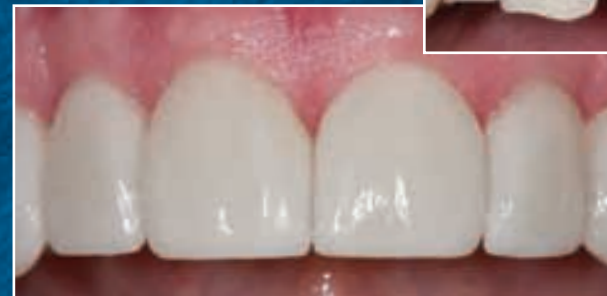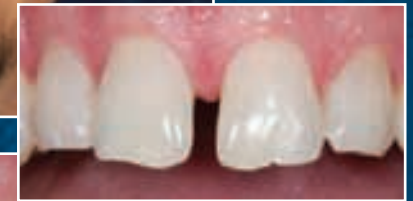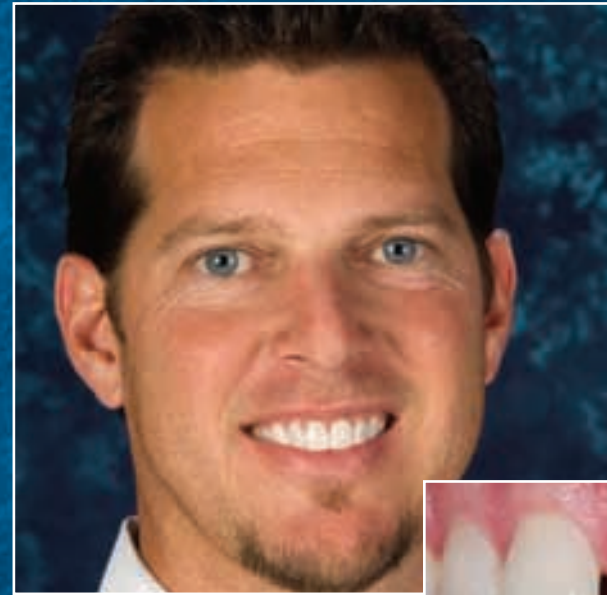Smile makeover...No shots...No needles...No drills

No Tooth Reduction



This 23-year-old female presented with multiple diastema and arch alignment problems. The patient was adamant that she did not want any preparation done to her teeth and preferred not to have any local anesthetic. Impressions were taken and study models sent to the lab as a no-prep case. Vivaneers were fabricated at 0.3mm thickness and were bonded into place using translucent veneer cement.

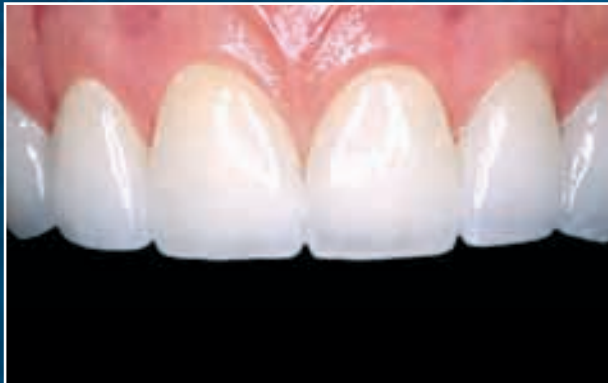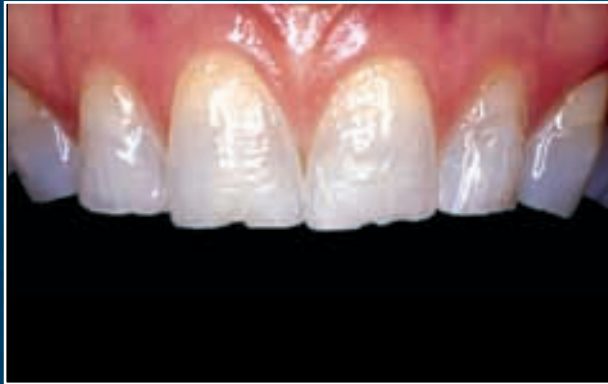No Tooth Reduction



This 31-year-old male presented with a midline diastema and worn, chipped incisal edges. Impressions were taken at his hygiene appointment and were sent to the lab for a diagnostic wax-up. The lab determined that the case was ideal for no prep veneers. Vivaneers were fabricated for teeth #5-#12 and bonded into place. The patient was extremely pleased with the final result of his new smile.

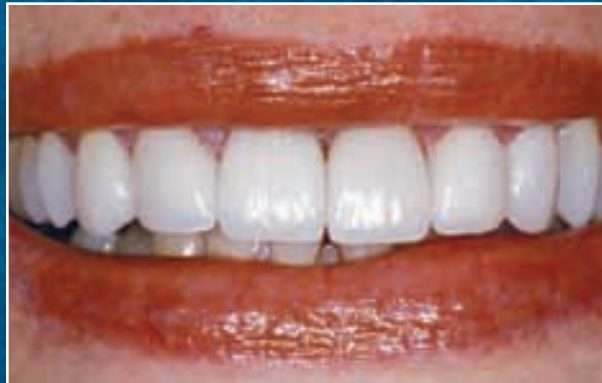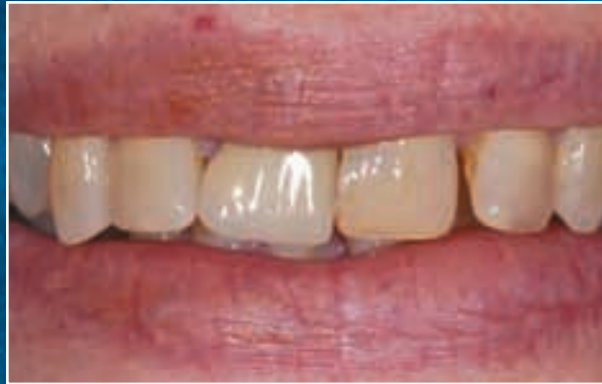Your dentist prescribes award winning veneers

Minimal Tooth Reduction



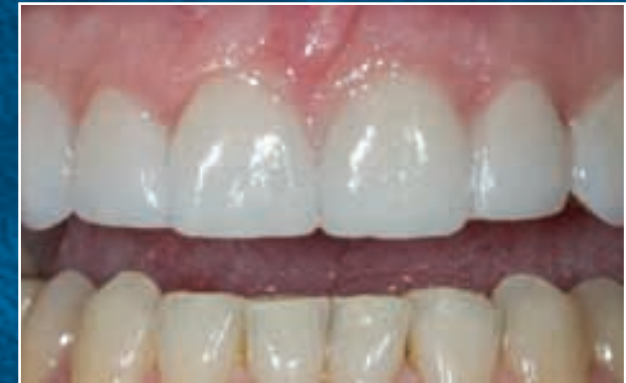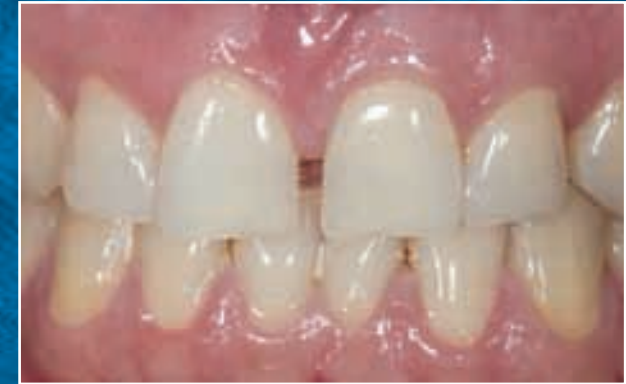This 51-year-old female patient had a history of parafunctional activity that caused excessive wear on the incisal edges of her anterior teeth. Also, the facial surfaces of her anterior teeth were rough and irregular making them prone to staining. A diagnostic wax-up helped determine the amount of preparation needed for the esthetic goal. Empress veneers from #5-#12 were used to restore her smile. The patient was happy with the final result.

Minimal Tooth Reduction



This 43-year-old female wanted to change the shade and alignment of her smile. Orthodontic treatment was suggested prior to placement of the veneers, but she declined. It was necessary to include veneers on the bicuspids and first molars to correct the alignment of the arch and create a pleasing buccal corridor. The teeth were aligned with a high speed handpiece prior to placement of the veneer depth cuts. Empress veneers were placed on teeth #3-#14.

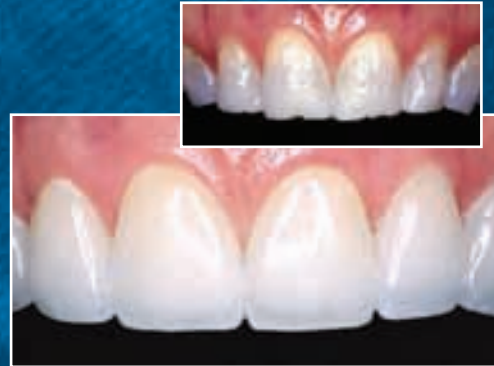No Tooth Reduction




This 37-year-old female has been unhappy with her midline diastema since high school but her family could not afford to afford to provide orthodontic treatment. It was not until she became an adult that she heard about porcelain veneers on a makeover TV show, but did not want to have her teeth prepared. After using before and after photos to explain her options, she decided to go with no prep veneers and is thrilled with the results.



Make the decision to restore your smile



Clinical dentistry by Michael DiTolla, DDS, FAGD.
Ceramics by Glidewell Laboratories



Glidewell veneers can be made razor-thin for cases with little to no preparation. For the most natural esthetics and the best gingival health, tooth preparation is recommended.

Depending on the clinical parameters, we use pressed ceramics in either IPS Empress® or Vivaneers™ made with PrismaTik ThinPress™ high-strength (155mpa flexural strength) leucite ceramic. Our proprietary ceramic application process guarantees you'll receive beautifully natural veneers consistently, case after case.

IPS Empress is a registered trademark of Ivoclar Vivadent, Inc. Vivaneers and PrismaTik ThinPress are trademarks of Glidewell Laboratories.

Your dentist chooses veneers from an award winning dental laboratory

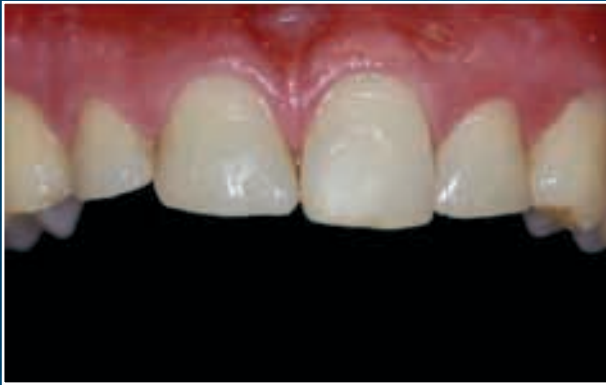

dental
townie
choice
awards.2006

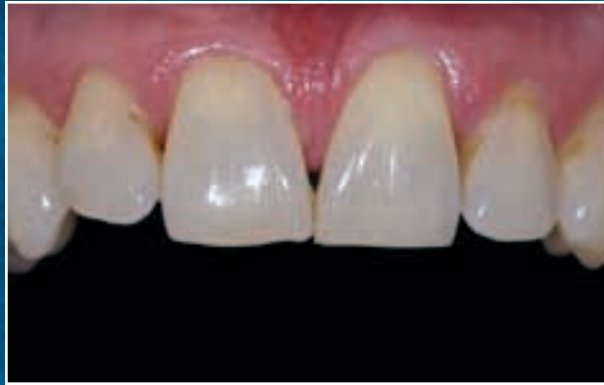*Glidewell Laboratories
voted best service/lab for
"Veneer & High Esthetic Cases"
2006 Townie Choice Awards®*

An investment that works every time you smile

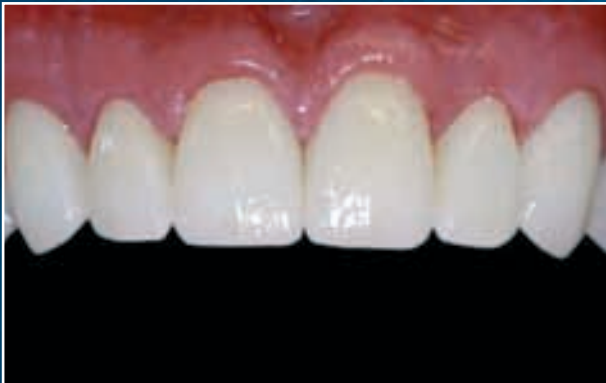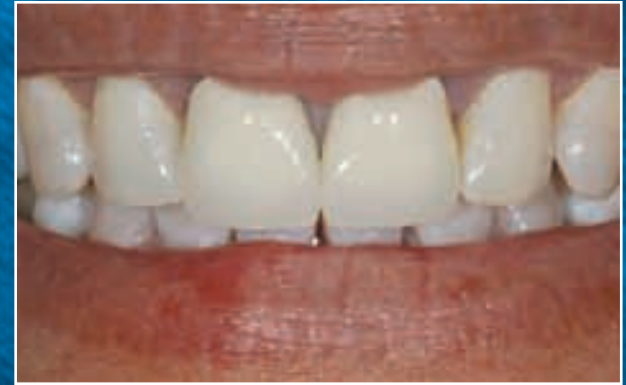Minimal Tooth Reduction



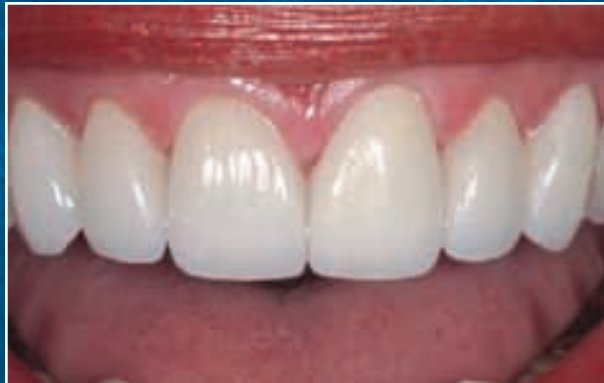No Tooth Reduction



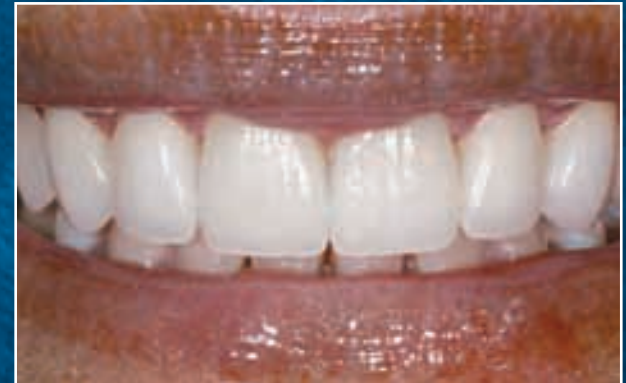Minimal Tooth Reduction



This 39-year-old male came to the office primarily concerned with his tooth size discrepancy. He also wanted to address his arch alignment problems. In order to correct these multiple cosmetic concerns, it was decided that prepared veneers would be the most suitable solution. Empress veneers were placed on teeth #4-#14 to give the patient the new smile he desired.



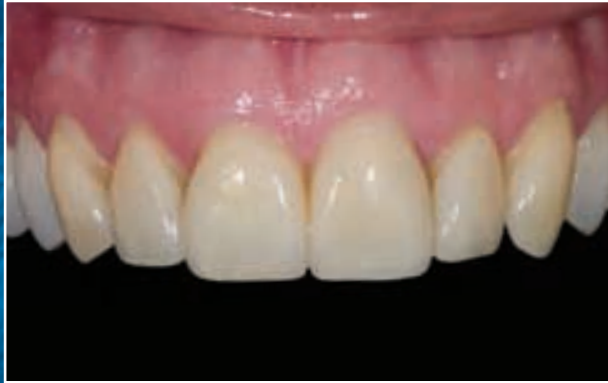This 41-year-old female patient presented with multiple esthetic concerns. She felt her front two teeth, #8-#9, were too long and she didn't like the black triangles between her two centrals. No preparation was needed. With the use of a soft tissue model to simulate the patient's gingival architecture, we were able to effectively close the black triangles with Vivaneers on teeth #4-#14.



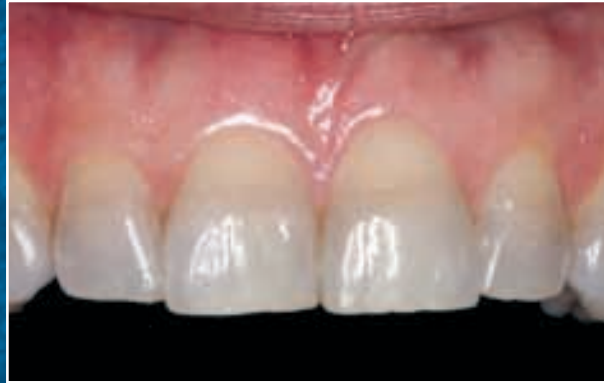This 35-year-old woman was displeased with the looks of her PFM crowns on teeth #8-#9. She wanted to replace them with all-ceramic crowns so that she didn't have to worry about dark metal margins showing up again. She did not like the shade or shape of her smile and decided to improve everything at once. Empress crowns were put on #8-#9 and Empress veneers on teeth #4-#7 and #10-#13.

Your dentist prescribes award winning veneers

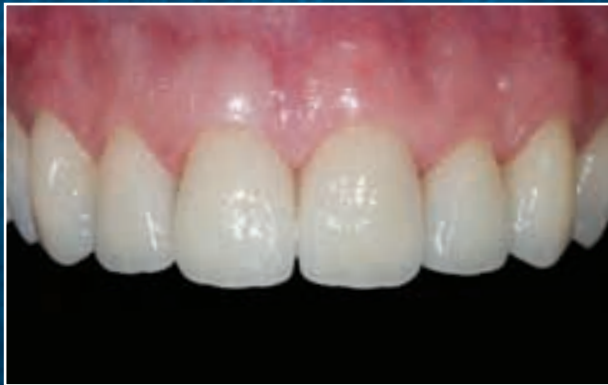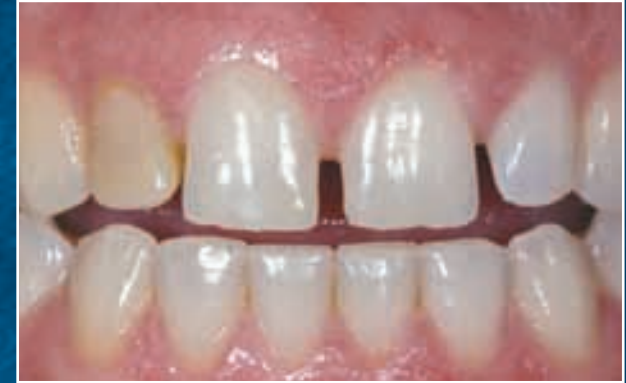Minimal Tooth Reduction



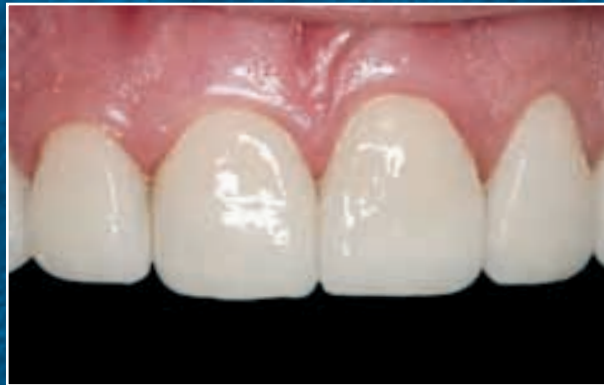Minimal Tooth Reduction



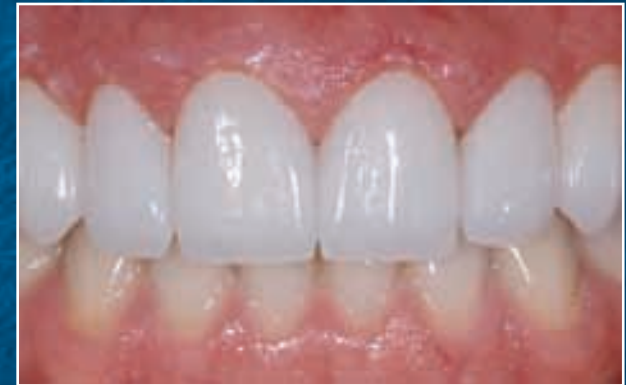No Tooth Reduction



This 29-year-old female patient was dissatisfied with her previous veneers on teeth #6-#11. As the before picture shows, these veneers were too yellow from the day they were put in. They were also too masculine as evidenced by the straight, flat incisal edges on teeth #8 and #9. Her new veneers not only match the shade of the existing teeth, but also demonstrate a markedly feminine shape and contour.



This 43-year-old female came in for a consultation regarding her tetracycline stained teeth. She always thought there was nothing she could do for her smile but full crowns, which she felt was too aggressive. A diagnostic wax-up allowed the patient to preview the esthetic objective. Empress veneers with a high value were used to mask the tetracycline staining and create a dramatic result.



This 35-year-old male was interested in improving his smile before starting his new job. He complained about the multiple spaces between his teeth and the shade of his endodontically treated lateral incisor. However, the patient was a dental phobic and did not want to have injections or tooth preparations. He was informed that a no-prep approach would work if we could do slight reduction on tooth #7.

Unconditional 7-year "free replacement" warranty against breakage